

# Validation of the Use of Homogeneous Sn-117m Colloid Radiosynoviorthesis in a GLP Osteoarthritis Rat Model

C Doerr<sup>1</sup>, A Bendele<sup>2</sup>, J Simon<sup>3</sup>, N Stevenson<sup>1</sup>, G Gonzales<sup>1</sup>



(1) R-NAV, LLC, The Woodlands, TX, USA, (2) Bolder BioPATH, Inc, Boulder, CO, USA, (3) IsoTherapeutics Group, LLC, Angleton, TX, USA



## Background

Radiosynoviorthesis (RSO) also known as radiosynovectomy, has been used since the 1950s outside of the United States to successfully treat arthritis and synovitis in humans. In the RSO procedure a colloidal radioactive nuclide is injected into the affected synovial joint space resulting in the reduction of pain, effusion, and inflammation caused by the synovitis. The isotope Sn-117m ( $t_{1/2}$  14d,  $\gamma$  159 keV, 86%), contains therapeutic monoenergetic conversion electrons (~140 keV, 112%) that have an ideal range in tissue of about 300  $\mu$ m. We have described the stability and characteristics of a new homogeneous Sn-117m colloid (HTC) with colloid particles averaging 5.33  $\mu$ m, (80% between 3.05  $\mu$ m and 9.63  $\mu$ m), which we used in a previous non-GLP rodent study. In the prior study we demonstrated that the Sn-117m colloid was highly retained in the injected joint, safe, and effective in all three doses used.

## Objective

The current study was designed similarly to the previous non-GLP study, with a greater number of rodents under GLP conditions to validate the results of the previous non-GLP trial, using the two HTC doses that did not cause significant synovitis.

## Materials & Methods

We used our previously described HTC in a surgically induced osteoarthritis rat model (n=90). All rats were treated with a single intra-articular injection of 2 $\mu$ Ci (low dose) or 10 $\mu$ Ci (high dose) in the left knee. Two control groups also were included. Data collection and analysis completed at various time-points included blood work, urine and fecal radiation excretion, histopathology, and bio-distribution. Rats were sacrificed at 7 days, 28 days (2  $t_{1/2}$ ), 42 days (3  $t_{1/2}$ ), and 70 days (5  $t_{1/2}$ ) after injection.

## Results

All animals behaved normally following surgery and HTC injection. Joint retention of the HTC, when correctly administered, was >99.0%. Blood work remained unremarkable throughout the study. Urinary and fecal cumulative radiation excretion averaged < 0.005% of the administered dose for all four days measured in a pre-determined subset of rats. Histopathology revealed that both treatment groups had slightly to significantly reduced lesion severity compared to controls, with beneficial effects noted at 7, 28, and 42 days (Figures 1-4). This positive effect was not sustained at 70 days (which is not unexpected in this rapidly progressive rat model). In all figures an "\*" identifies statistical significance compared to the model control without treatment (left column).

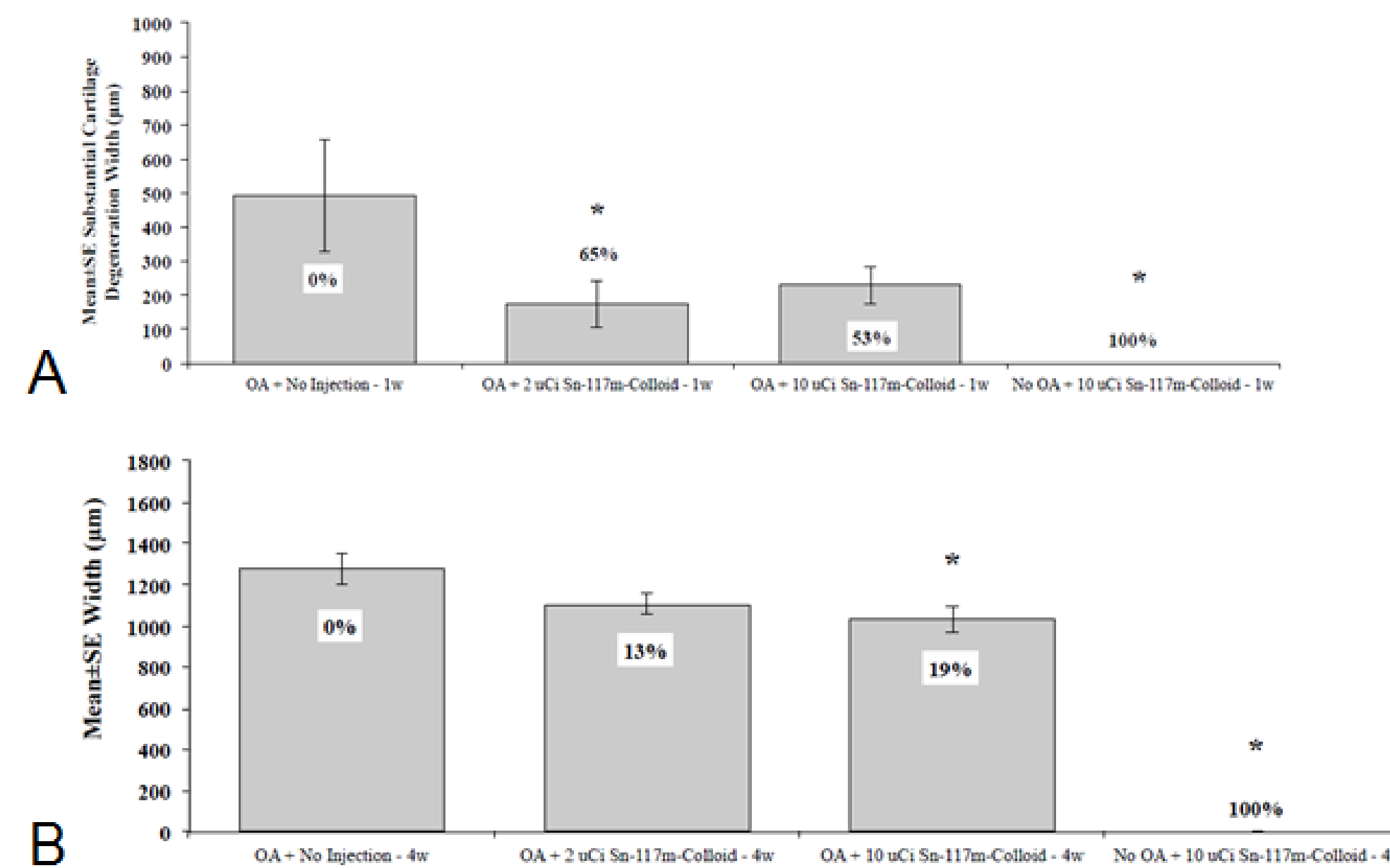


Figure 1. Substantial Cartilage Degeneration Width. (A) Low dose HTC is significantly better than the model control at 1 week. (B) High dose HTC is significantly better than the model control at 4 weeks.

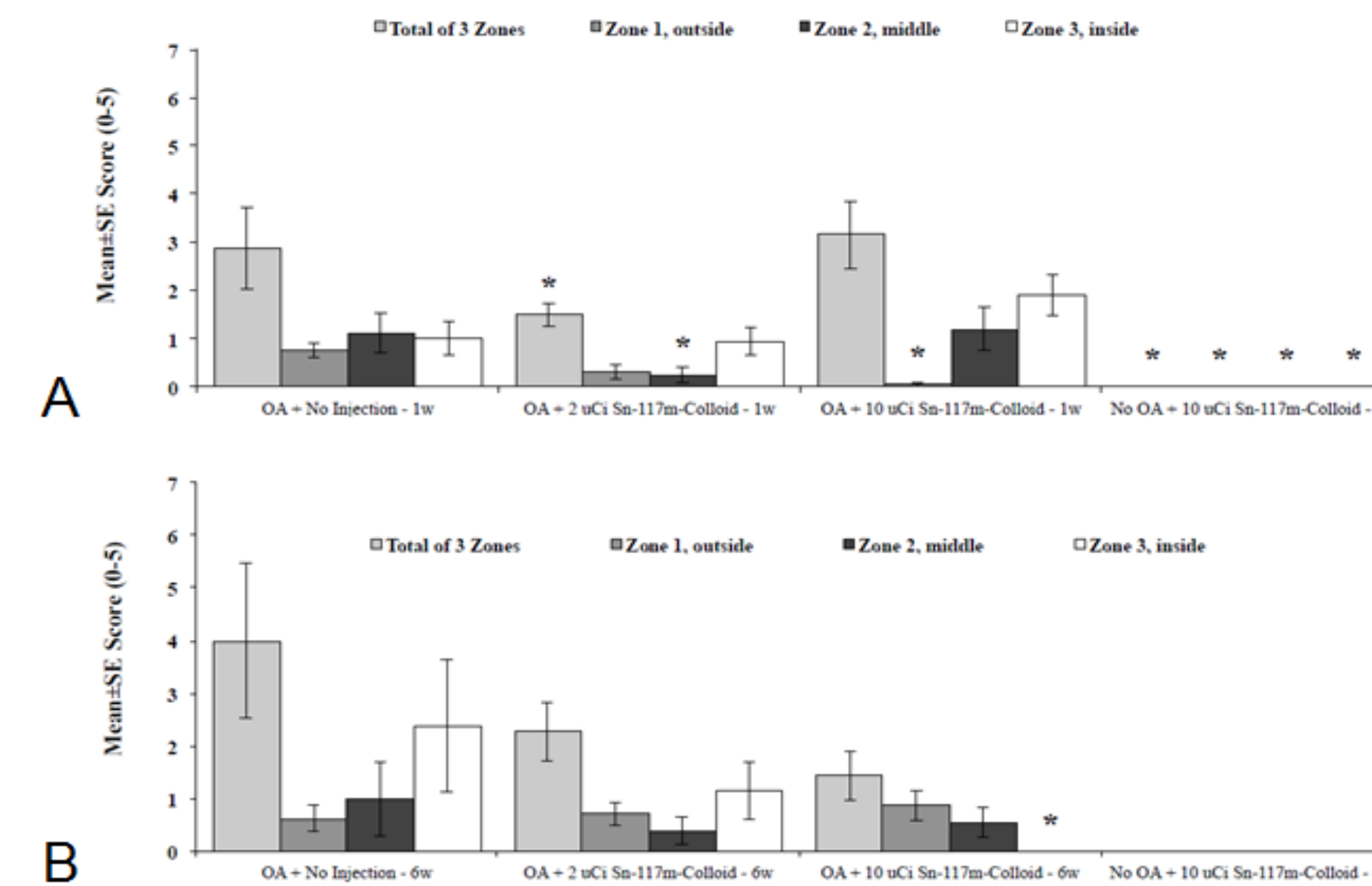


Figure 2. Femoral Cartilage Degeneration Score. (A) Low dose HTC has significantly lower femoral cartilage degeneration score than the model control in Zone 1-3 (total) and Zone 2. High dose HTC has significantly lower score than the model control in Zone 1 at 1 week. (B) High dose HTC has a significantly lower score than the model control in zone 3 at 6 weeks.

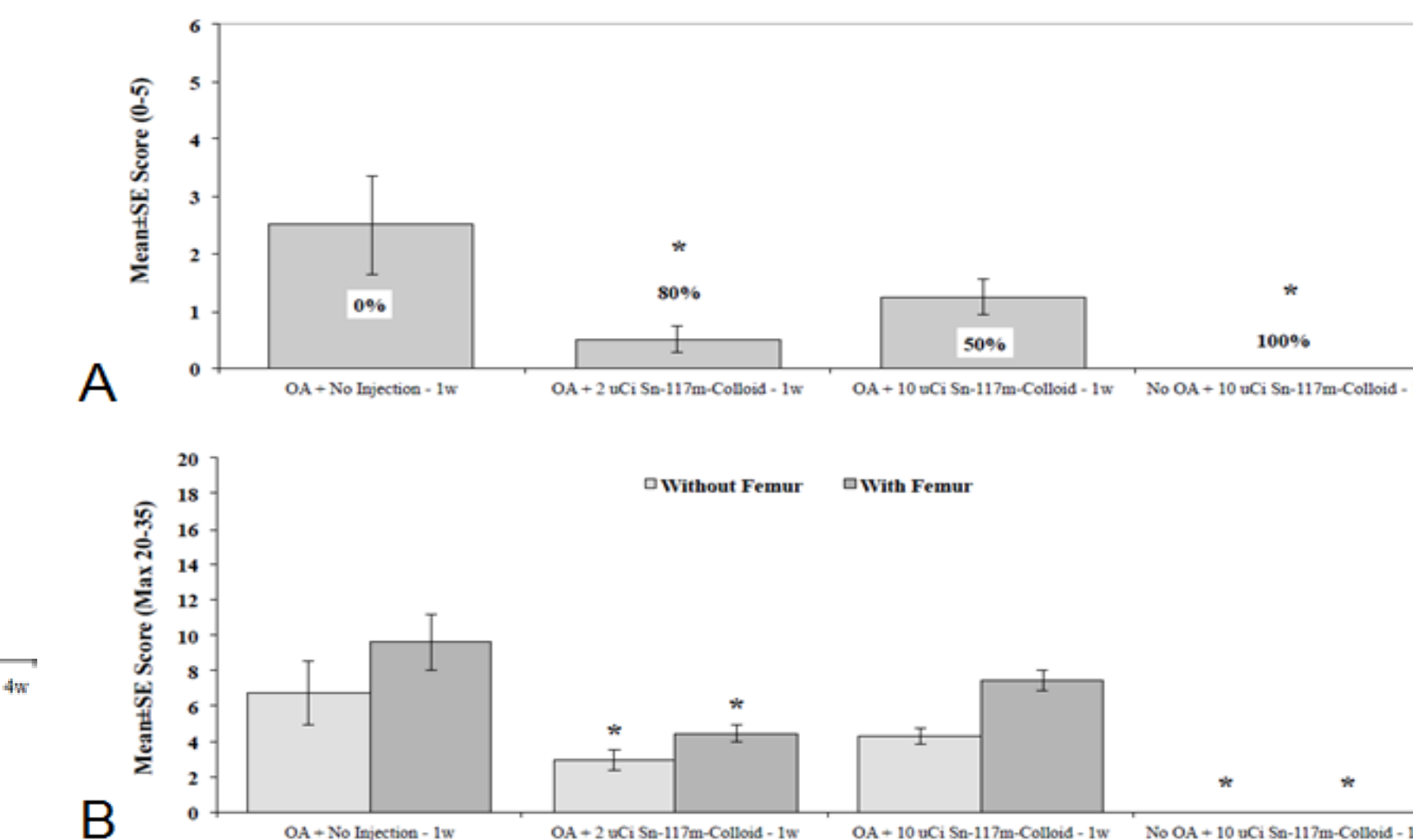


Figure 3. Osteophyte and Total Joint Score. (A) Low dose HTC has significantly fewer osteophytes than the model control at 1 week. (B) Both low and high dose HTC have significantly better total joint score than the model control at 1 week.

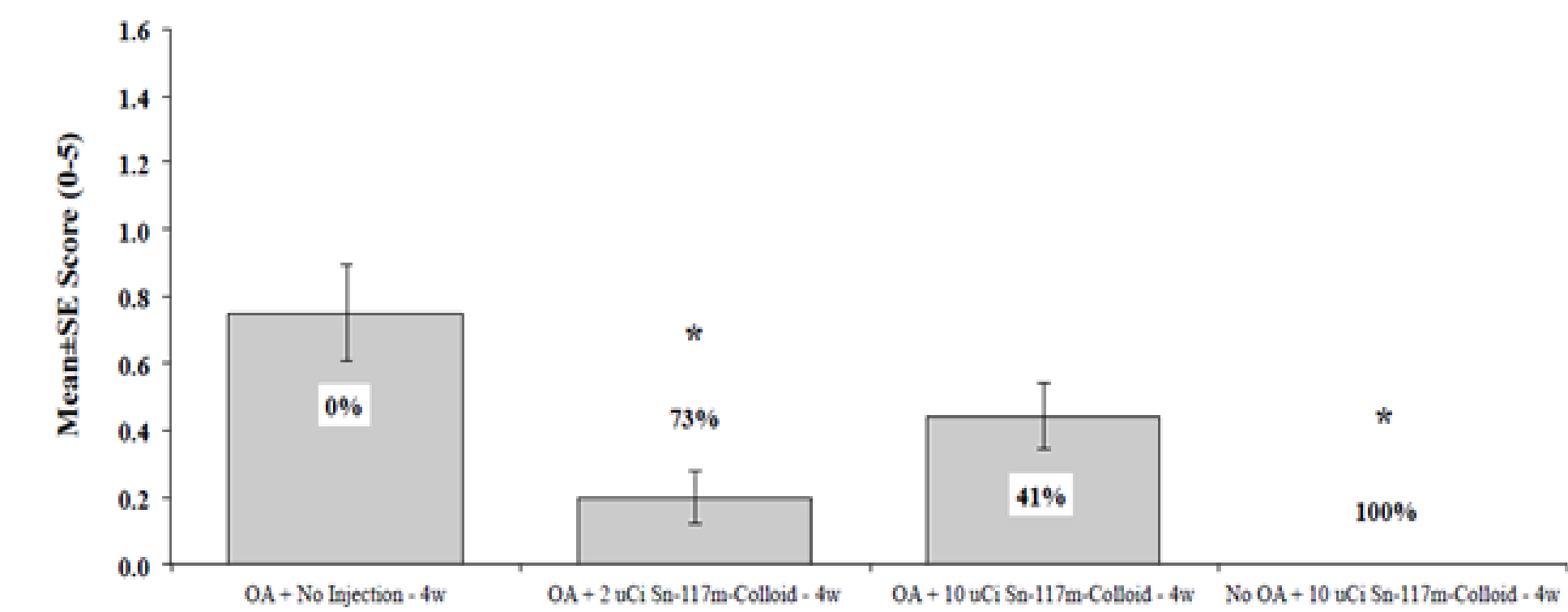


Figure 4. Synovitis. Low dose HTC has significantly less synovitis than the model control at 4 weeks.

## Conclusions

These results validate and build upon those of prior non-GLP studies, and lead us to conclude: (1) HTC is significantly retained in the joint space when properly administered thus mitigating the likelihood of unintended distal tissue irradiation, (2) following administration, there are no clinical safety concerns as noted by normal rat behavior, (3) fecal and urinary radiation excretion is nominal immediately following HTC administration, suggesting the ability to rapidly release rats from radiation isolation, (4) histopathology indicates a disease modifying positive therapeutic effect of two doses in this rat model. As a result of these positive data, we have begun a pivotal trial to treat naturally occurring elbow osteoarthritis in dogs with a weight-appropriate dose of HTC.

## Disclosures

Doerr, Stevenson and Gonzales: Employment/ownership in R-NAV, LLC (trial sponsor)