



# PRECLINICAL EXPERIENCE WITH $^{117m}\text{Sn}$ COLLOID AS A RADIOSYNOVIORTHESIS AGENT FOR TREATMENT OF CANINE ELBOW JOINT OSTEOARTHROSIS

J. LATTIMER<sup>1</sup>, K. SELTING<sup>1</sup>, J. LUNCEFORD<sup>1</sup>, J. HOLLAND<sup>1</sup>, J. SIMON<sup>2</sup>,  
N. STEVENSON<sup>3</sup>, C. DOERR<sup>3</sup>, J. DONECKER<sup>3</sup>

<sup>1</sup> University of Missouri, Columbia Missouri 65211

<sup>2</sup> Isotherapeutics Group, Angleton TX 77515

<sup>3</sup> Convetra, Inc., The Woodlands, TX 77380

## Disclosure:

The work in this project was supported by a contract between Convetra, Inc. and the University of Missouri.

# Osteoarthrosis/Osteoarthritis

Most common clinical disorder in dogs and man

- ▶ Result of joint injury
  - ▶ Trauma
  - ▶ Instability
    - ▶ Developmental disorders –
      - ▶ Fragmented Medial Coronoid
      - ▶ Canine Hip Dysplasia
      - ▶ Degenerative Cranial Cruciate Ligament Syndrome
  - ▶ Infection – bacterial, viral, rickettsial
  - ▶ Autoimmune disease

# Osteoarthrosis/Osteoarthritis

Most common clinical disorder

## ▶ Progression

- ▶ Synovial inflammation – earliest stage of joint degeneration
  - ▶ Results from inciting insult, especially if ongoing
- ▶ Ligamentous and capsular injury
- ▶ Cartilage injury
- ▶ Subchondral and perichondral bone injury – latest stage of disease

Progression rate



# Radiosynoviorthesis

- ▶ Use of a radioisotope preparation to partially ablate the synovium and reduce inflammation and pain in a joint thereby slowing progression of osteoarthritis
- ▶ Challenges
  - ▶ Retention of the isotope in the joint tissues
  - ▶ High local radiation dose to synovium
  - ▶ Minimal intrinsic chemical toxicity to joint structures
  - ▶ Minimal radiation dose to cartilage, bone and ligaments/tendons
  - ▶ Minimal radiation dose to rest of patient and others

# $^{117m}\text{Sn}$ Colloid (Synovetin OA™)

- ▶  $^{117m}\text{Sn}$  - Half-life 14 days
- ▶ Emissions
  - ▶ Conversion electrons – 140 keV – <300 micron range in tissue
    - ▶ Insufficient energy to reach bone and tendons
  - ▶ Gamma photons – 158 keV – imageable on gamma camera
- ▶ Colloid size - ~(3 – 15  $\mu\text{m}$ )
  - ▶ Promotes retention in joint through engulfment by joint macrophages
  - ▶ Stable in suspension for 5 weeks or more.
  - ▶ Easily suspended and injected

# Prior studies

- ▶ Prior studies performed in rats
  - ▶ Lewis rat meniscal tear model > 150 rats
  - ▶ A range of doses were treated
  - ▶ Duration of trial was 42 days
  - ▶ Confirmed decrease in inflammation on histological examination
  - ▶ Minimal adverse effects on synovium except high dose group
  - ▶ No cartilage, bone or ligamentous injury
  - ▶ > 99% of isotope retained in the joint based on biodistribution studies

# Study design

- ▶ Five young adult purpose-bred female hounds
- ▶ Minimum 5 days acclimation
- ▶ CBC, serum chemistries, urinalysis
- ▶ Radiographs, PET/MRI, post injection nuc. med. scan
- ▶ Joint fluid cytology and analysis
- ▶ Injection of left elbow with  $^{117m}\text{Sn}$  colloid
  - ▶ 2.5 millicuries – normalized to 22.75 kg BW by BSA
    - ▶ Approximates highest non-injurious dose from rats.
- ▶ Daily observation for lameness



# Study Design Continued

- ▶ 24 hours after injection – NM scan of elbow and abdomen
- ▶ Collection of blood, urine and feces for 5 days
  - ▶ Standard size samples counted in swipe counter
  - ▶ Total excreted urine and feces activity calculated
- ▶ 42 days after injection - all clinical pathology and imaging studies repeated
- ▶ 47 - 49 days after injection – euthanasia & postmortem
  - ▶ All major organs collected and counted for total activity
  - ▶ Histopathology of all major organs
  - ▶ Histopathology and autoradiography of joint tissues

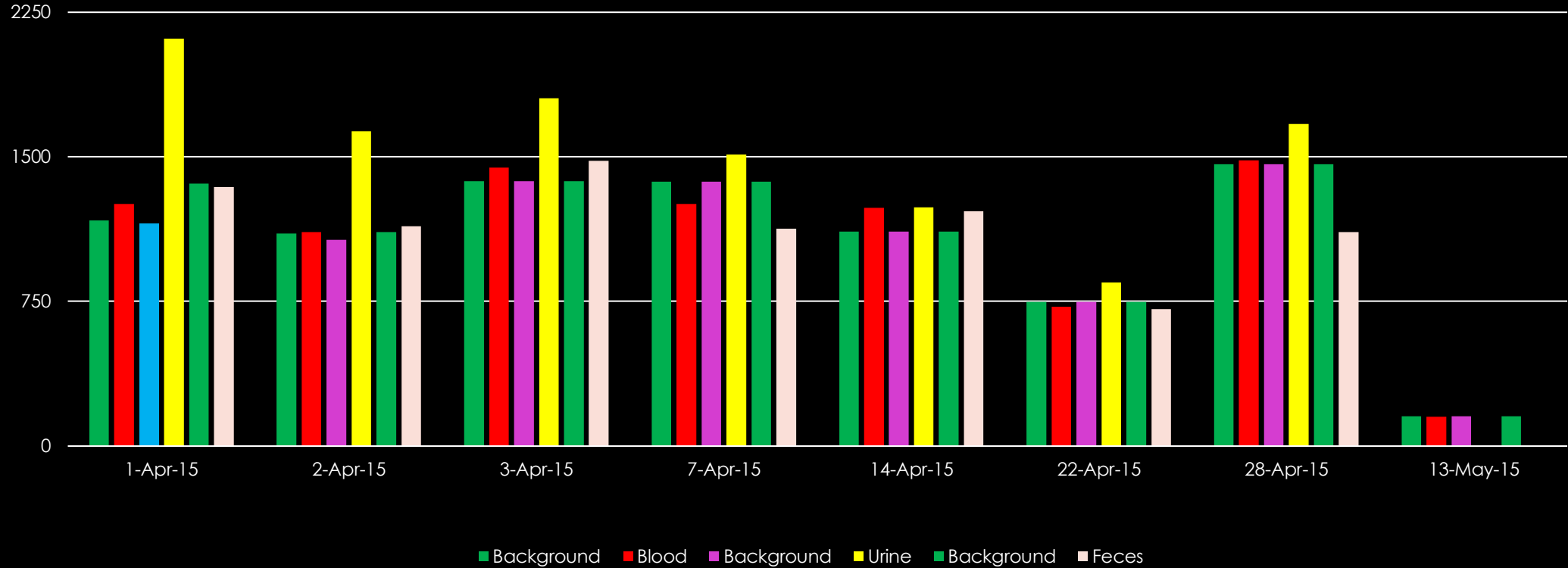
# Results

- ▶ No dog exhibited any lameness after injection
- ▶ NM confirmed retention in joint for up to 7 days
- ▶ Urine and feces collection indicated  $< 1\%$  average excretion
- ▶ Imaging studies were normal and static between studies

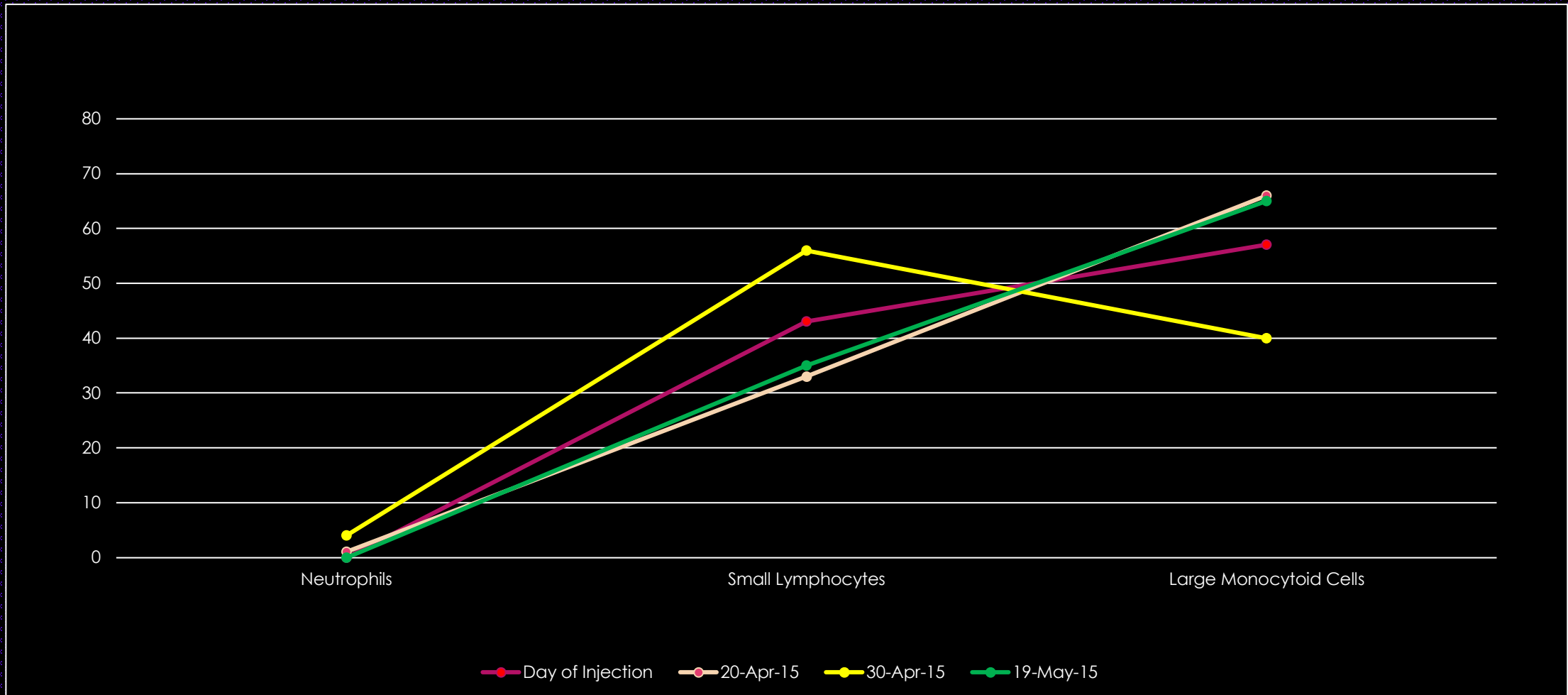


# Blood, Urine and Feces Counts – post injection

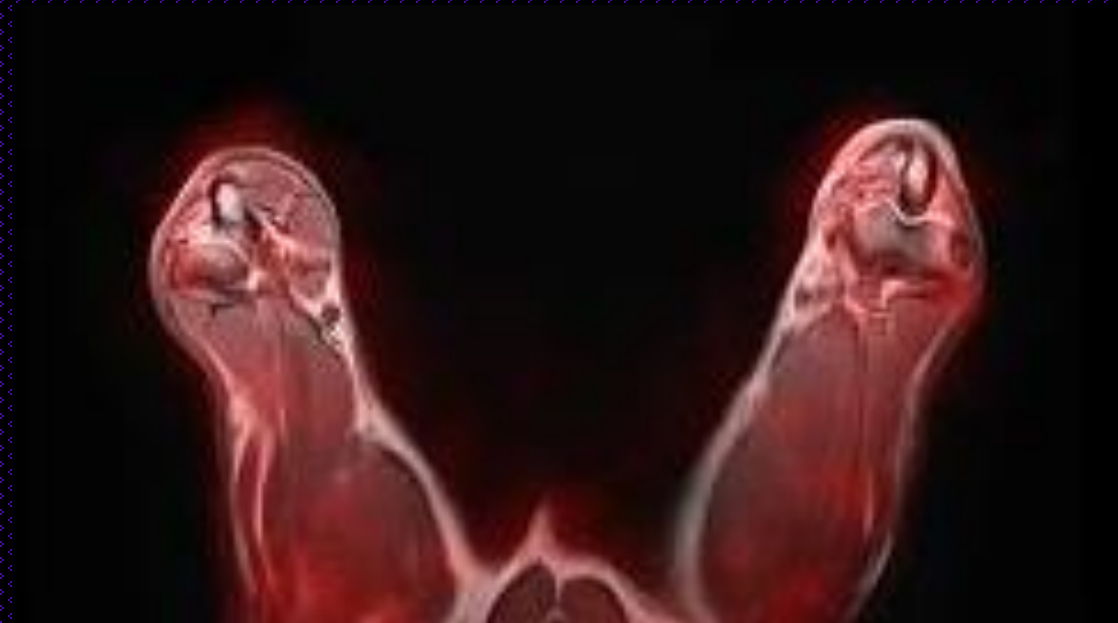
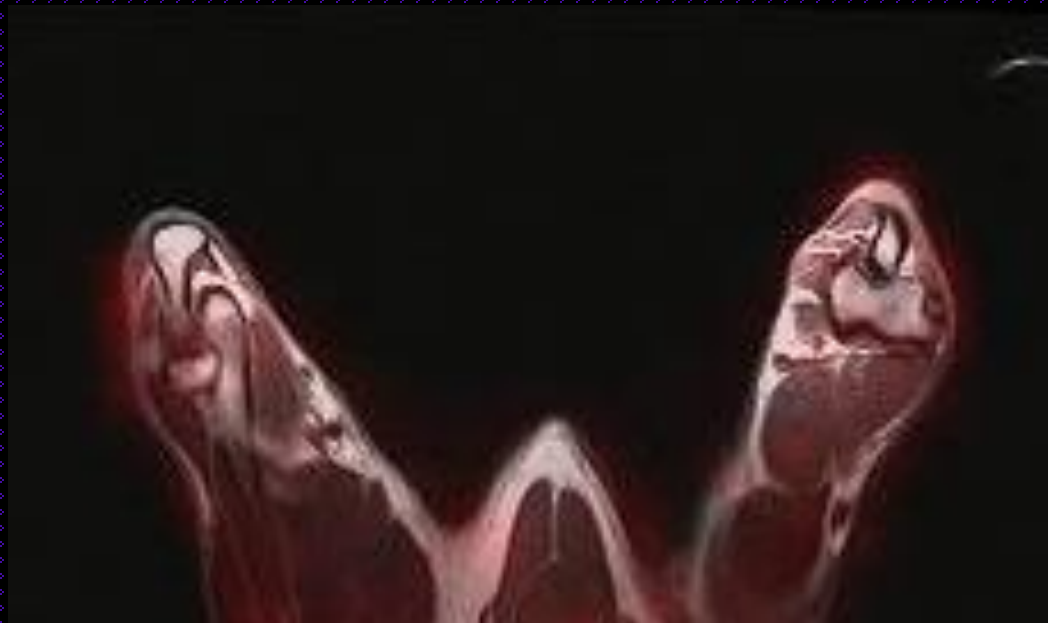D15-54

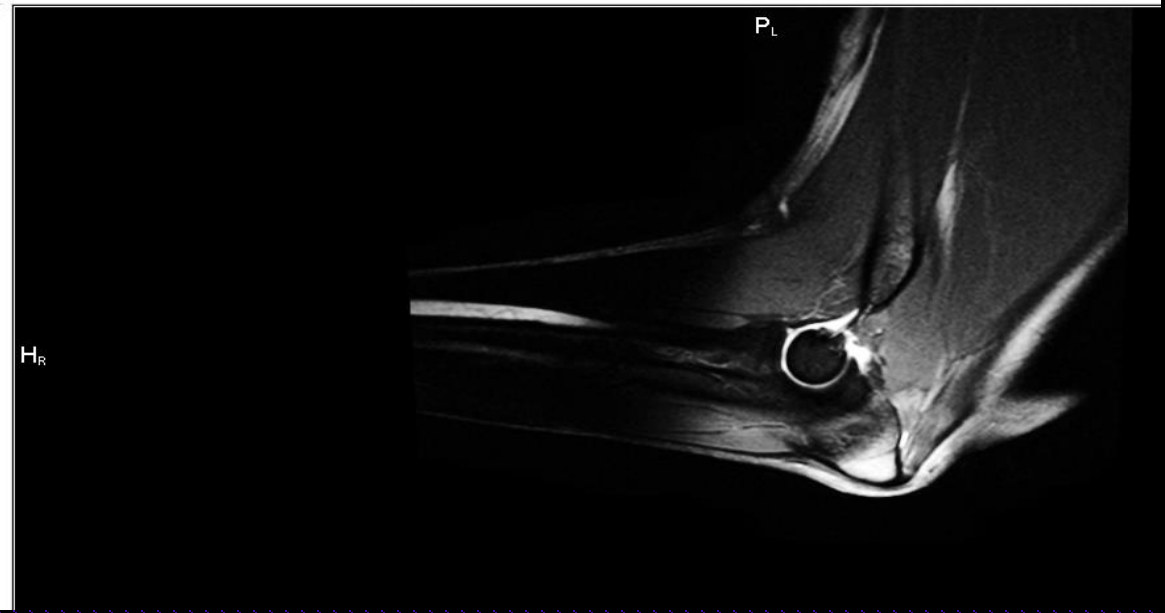
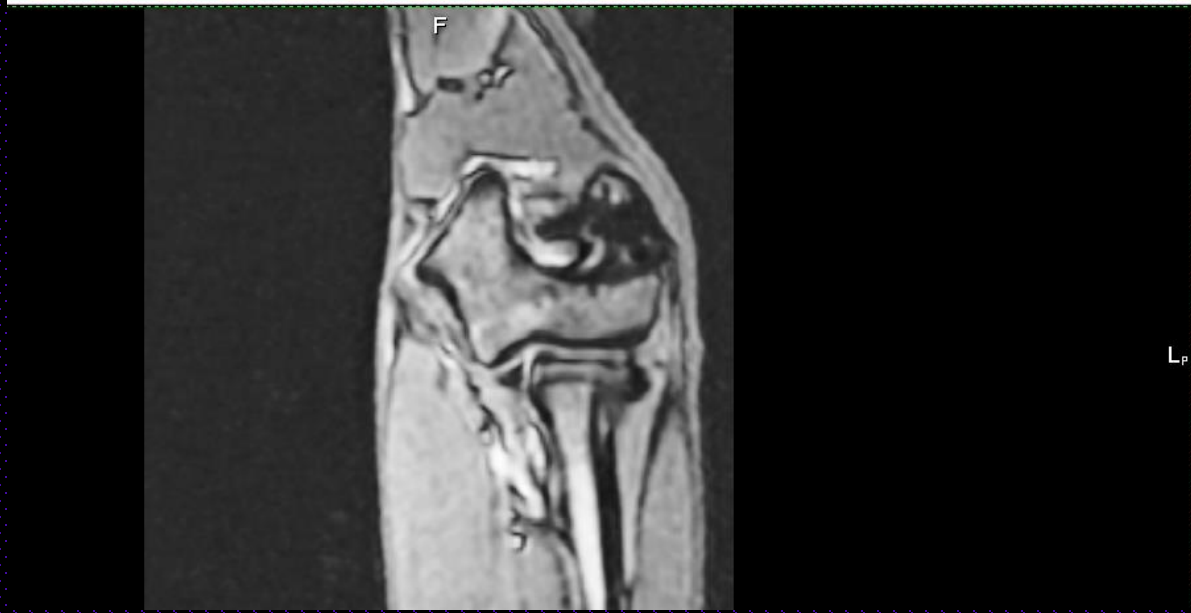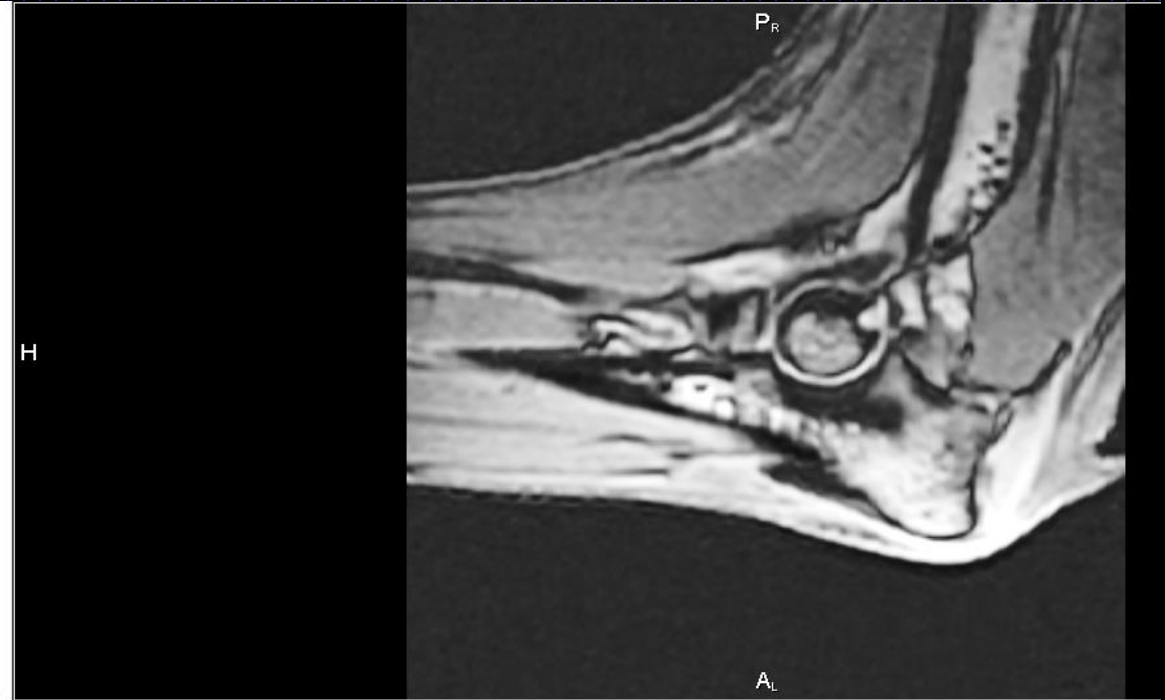
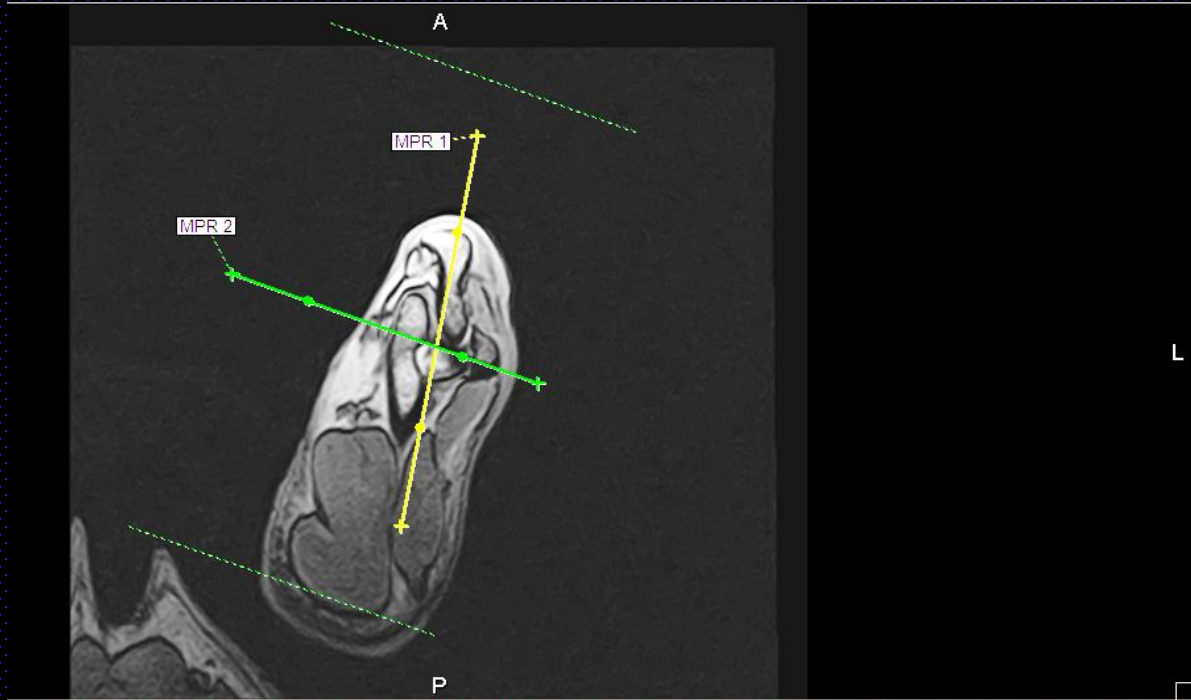


# Synovial Fluid Cell Counts – Direct Smear



# PET/MRI images – day 0 & 42





# Post mortem studies

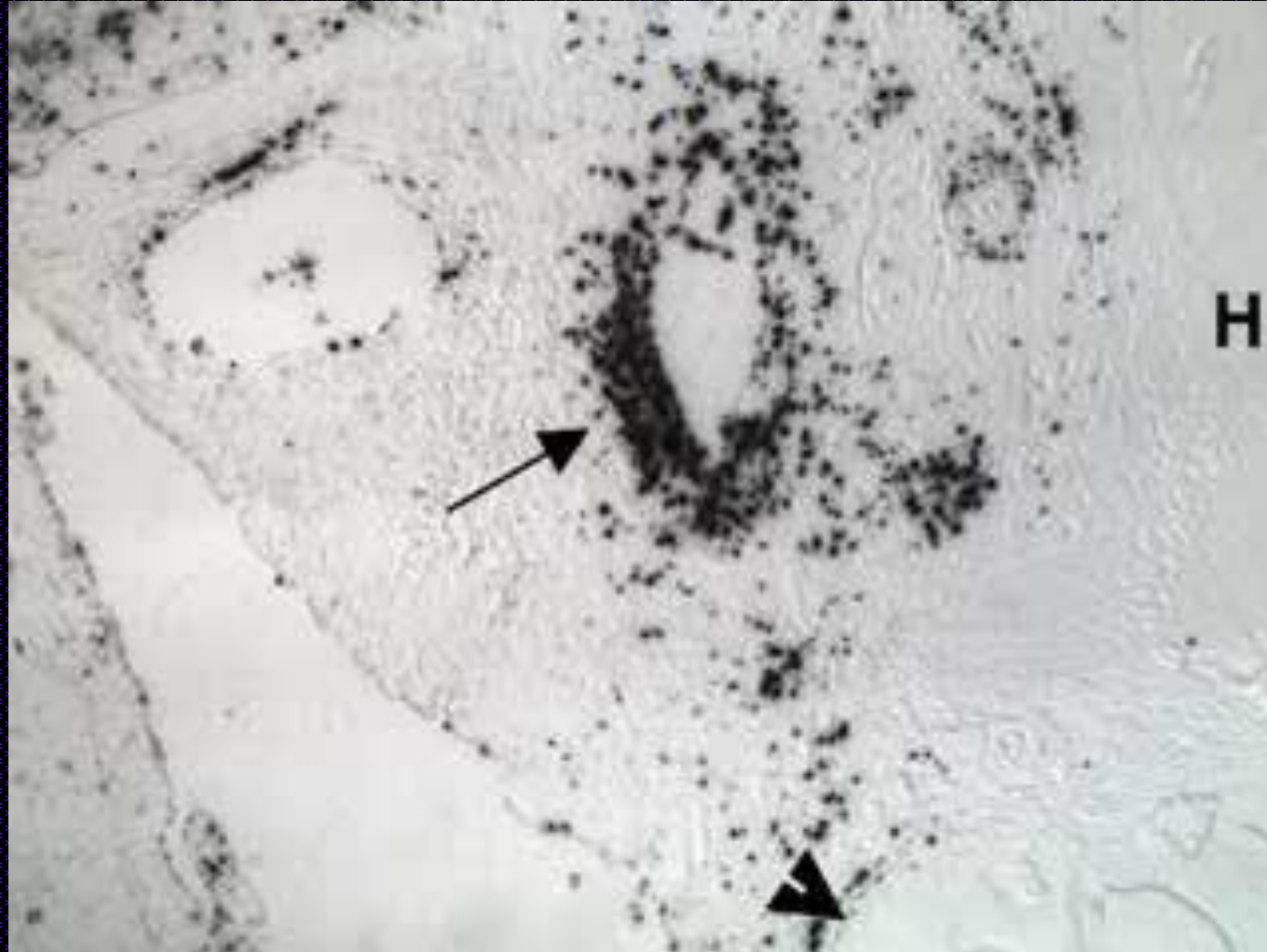- ▶ No histologic abnormalities were found in organs or joints
- ▶ Organ and elbow activity indicated > 99% retention in elbow
- ▶ Micro autoradiography confirmed synovial localization



# Post mortem studies

Tissue retention at 47-49 days								
							millicuries	Decay Geometry
	7152473	7152474	7152475	7152476	7152477	Average	retained	corrected mCi
R Prescapular LN	826	824	856	925	917	870	0.00000039	0.000013
L Prescapular LN	879	878	54034	18356		18537	0.00000835	0.000270
Heart	883	812	833	860	1006	879	0.00000040	0.000013
Lung	870	959	896	893	848	893	0.00000040	0.000013
Liver	1165	2535	5642	1727	2069	2627	0.00000118	0.000038
Kidney	920	1133	901	902	954	962	0.00000043	0.000014
Spleen	1574	1427	1686	1197	1379	1453	0.00000065	0.000021
Bladder	1519	855	847	825	861	981	0.00000044	0.000014
Bile from Gallbladder	850	813	831	857	871	844	0.00000038	0.000012
Sums							0.00000000	0.000408

# Post mortem autoradiography of synovium



# Conclusions

- ▶  $^{117m}\text{Sn}$  colloid (Synovetin™) should be evaluated as a radiosynoviorthesis agent in dogs
  - ▶ It was retained in the elbow joints with > 99% localization
  - ▶ The agent was well tolerated by the animals
  - ▶ No adverse reactions to the injection were detected
  - ▶ Further trials in dogs with naturally occurring clinical arthritis are needed to evaluate the efficacy of this agent

# Future Studies

- ▶  $^{117m}\text{Sn}$  colloid (Synovetin™) is currently being evaluated in a multicenter trial for treatment of clinical lameness in dogs with grade 1 or 2 elbow arthritis.
- ▶ Trials are currently being planned for evaluation of this agent in the treatment of osteoarthritis in a limited equine study.
- ▶ Evaluation of efficacy in other joints and more advanced osteoarthritic conditions in dogs

# References:

- ▶ The role of synovitis in pathophysiology and clinical symptoms of osteoarthritis, Sellam, J. & Berenbaum, F. *Nat. Rev. Rheumatol.* 6, 625–635 (2010)
- ▶ New insights on cell death from radiation exposure, Kevin M Prise, Giuseppe Schettino, Melvyn Folkard, Kathryn D Held, *Lancet Oncol* 2005; 6: 520–28
- ▶ Role of inflammation in the pathogenesis of osteoarthritis: latest findings and interpretations, Sololove J, Lepus C; *Ther Adv Musculoskel Dis*, 2013 5(2) 77-94
- ▶ Direct in vivo evidence of activated macrophages in human osteoarthritis, V.B. Kraus\*, G. McDaniel, J.L. Huebner, T.V. Stabler, C.F. Pieper, S.W. Shipes, N.A. Petry, P.S. Low, J. Shen, T.A. McNearney, P. Mitchell, in press, *Osteoarthritis and Cartilage* (2016)